



PRESENTING CLINICAL SIGNS

History: Grade 2/6 murmur. Owner notes abnormal breathing, but not present during exam. VHS 13.9. Started on pimobendan 5 mg BID after previous echocardiogram.

DATE

8/1/22

ECHOCARDIOGRAPHIC FINDINGS

2D, M-mode, and Doppler study.

PERFORMED BY:

Kim Liedberg

INTERPRETED BY

Keith Blass, DVM,
MS, DACVIM
(Cardiology)

Left atrial size is normal. The mitral valve leaflets are mildly thickened, and a mild jet of mitral regurgitation is present. Left ventricular dimensions are normal. Left ventricular systolic function is normal. The aorta and aortic valve appear normal, though there is mildly increased flow velocity in the ascending aorta. Right atrial and right ventricular dimensions are normal. The tricuspid valve leaflets are mildly thickened, and a mild jet of tricuspid regurgitation is present. TR velocity does not suggest the presence of pulmonary hypertension. The pulmonary artery and pulmonic valve are normal. No shunting lesions are visualized. No heartworms are visualized. No pericardial effusion or cardiac masses are seen.

PATIENT

Nona Zakosek

LA - 38.8 mm
LVIDd - 37.1 mm
LVIDs - 22.0 mm
FS - 40.7%
RA - 26.2 mm
LVOT - 1.40 m/s
RVOT - 0.99 m/s
TR - 2.12 m/s

SPECIES

Canine

ASSESSMENT/RECOMMENDATIONS

Degenerative mitral and tricuspid valve disease

BREED

Vizsla/Pitbull Mix

This examination demonstrates mild regurgitation of blood across Nona's mitral and tricuspid valves resulting from degenerative valve disease. The hemodynamic effects of each of the regurgitations also appear to be mild, as Nona does not have secondary dilation of any of her cardiac chambers. As such, Nona's valvular diseases appear to be well-compensated, and it's unlikely that her reported abnormal breathing is cardiogenic in origin.

SEX

FS

While Nona's current therapy with pimobendan may be continued if desired, no therapy has been proven to be beneficial at this stage of her valvular diseases.

A recheck echocardiogram is recommended in 6 months to monitor for disease progression.

AGE

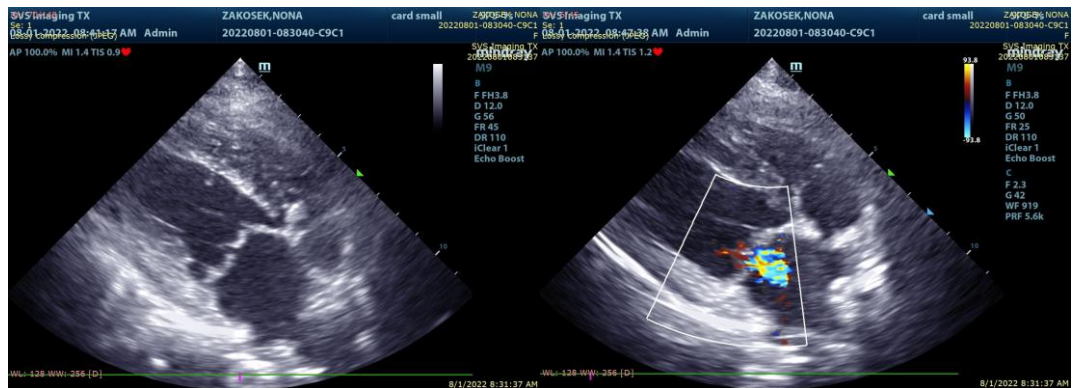
13 y

WEIGHT

61.2 lb

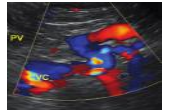
HOSPITAL NAME

SVS Imaging WI



REFERRING VET

Dr. Dominquez



The information and recommendations provided are based on the images presented by the referring veterinarian. No evaluation can be communicated regarding pathology that was not visible in the image/video clips provided.

DATE

8/1/22

Thank you for this referral. If the clinical or image interpretation does not parallel your findings or if I can be of any further assistance please contact me.

PERFORMED BY:

Kim Liedberg

Keith Blass, DVM, MS, DACVIM (Cardiology)
KeithBlass@gmail.com
631-804-5754

INTERPRETED BY

Keith Blass, DVM,
MS, DACVIM
(Cardiology)

PATIENT

Nona Zakosek

SPECIES

Canine

BREED

Vizsla/Pitbull Mix

SEX

FS

AGE

13 y

WEIGHT

61.2 lb

HOSPITAL NAME

SVS Imaging WI

REFERRING VET

Dr. Dominquez